

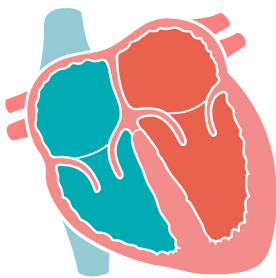
ECHOCARDIOGRAPHY

Understanding when to use POCUS ECHO

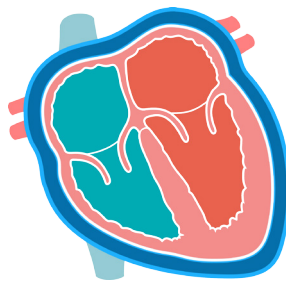


*Is heart contractility normal?
Is there a pericardial effusion?
Is the heart chamber size normal?*

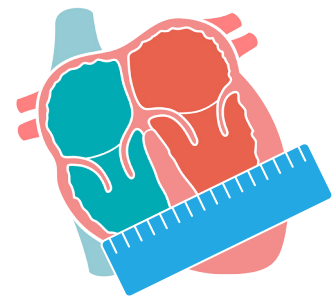
Whenever the knowledge of contractility, pericardial effusion, or chamber size will help with patient assessment perform a POCUS ECHO.



Contractility



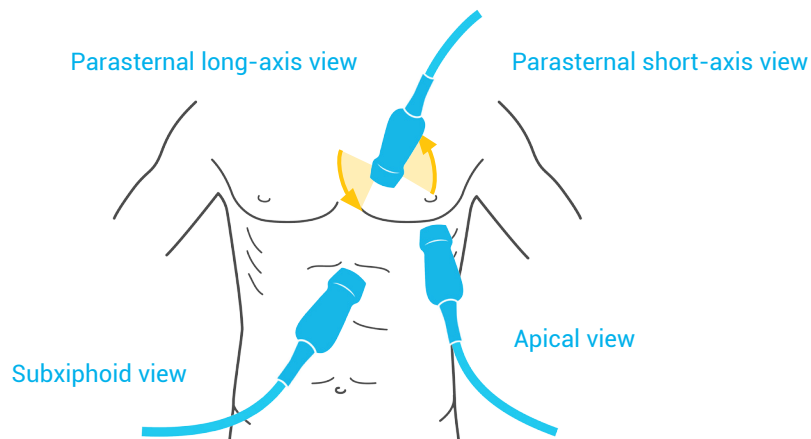
Pericardial effusion



Chamber size

Views

There are four views:



Marker controversy

Cardiologists have traditionally placed the dot to the left of the screen when performing ECHOs. However, POCUS users leave it on the right of the screen. To accommodate for this difference, the probe position

is changed 180 degrees when acquiring the images, hence producing the same exact image orientation on the screen.

