

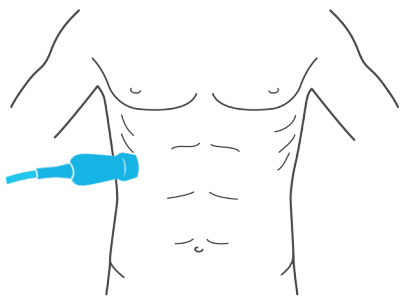
# HEPATOBIILIARY

## Obtaining the view of the gallbladder

There are three possible methods to acquire the images: coronal cross-section, subcostal X-7, or subcostal X-12.

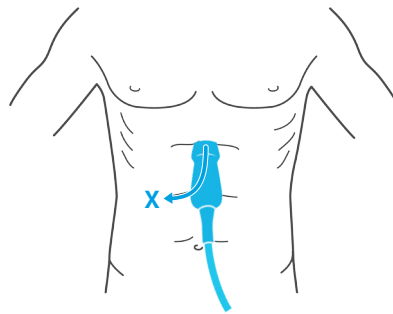
### Coronal cross-section

Place probe between the lower rib spaces and fan.



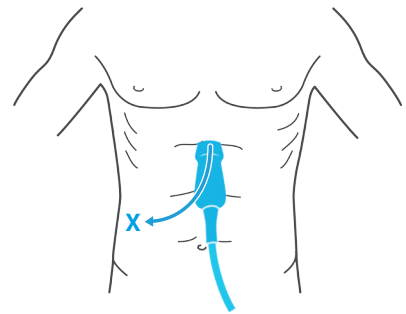
### Subcostal X-7

Starting at the xiphoid process, slide the probe under the costal margin 7 cm to the right side.

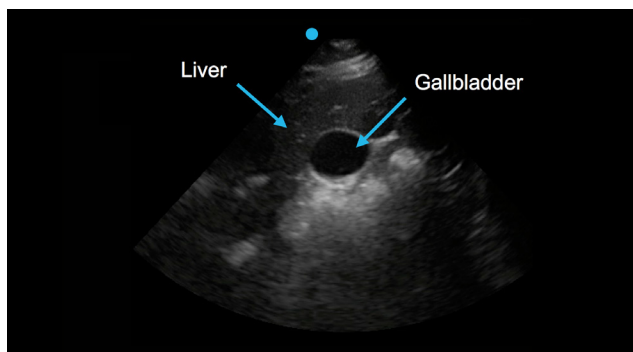


### Subcostal X-12

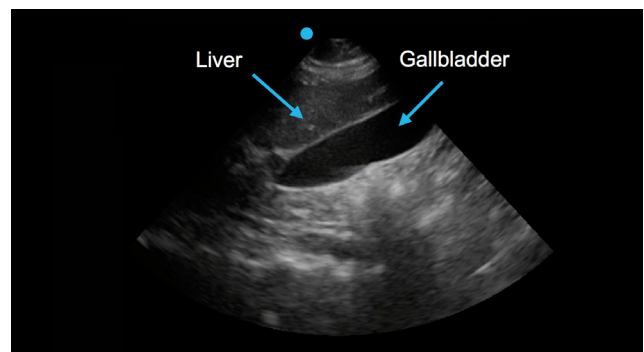
Starting at the xiphoid process, slide the probe under the costal margin 12 cm to the right side.



Using a low frequency probe, place the probe in on of the three positions. Hold the indicator to the patient's right for a short-axis view and to the patient's head for a long-axis view.



Gallbladder, short-axis view



Gallbladder, long-axis view