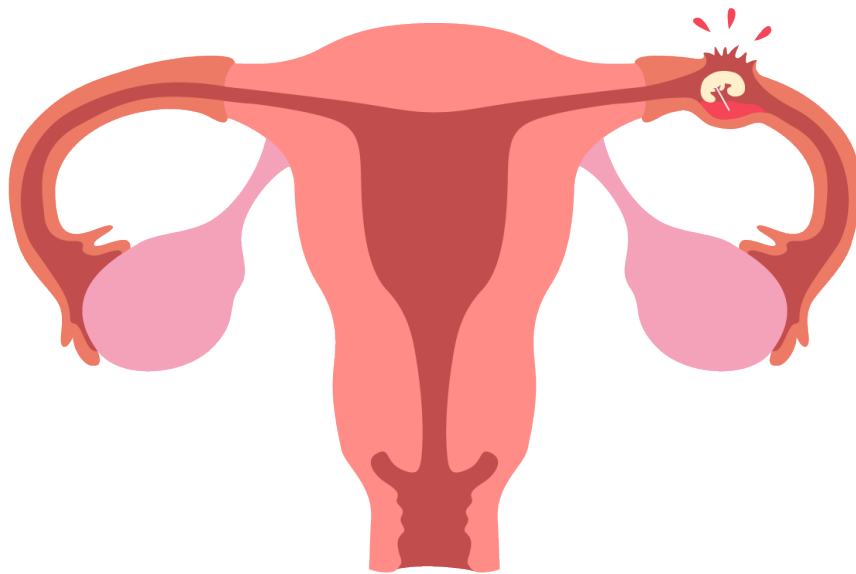


FIRST TRIMESTER PREGNANCY

Evaluating for an ectopic pregnancy

Given the right clinical setting, the absence of a definitive intrauterine pregnancy visualized on ultrasound, should be considered an indicator of ectopic pregnancy, until proven otherwise.



Free fluid

Free fluid is often visualized around the uterus, and/or in the right upper quadrant, in a ruptured ectopic pregnancy.

