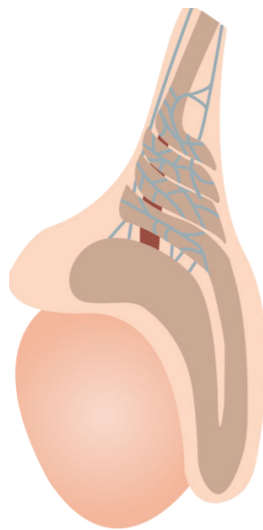


Scrotal ultrasound

RECOGNIZING WHEN TO PERFORM SCROTAL ULTRASOUND

Scrotal and testicular complaints are a common reason for males to present for care.

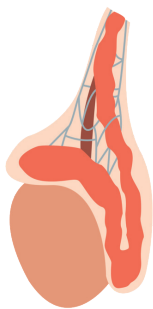
The primary role of scrotal point-of-care ultrasound is to evaluate for testicular torsion. Torsion is a time-sensitive diagnosis, and in the absence of comprehensive imaging, point-of-care ultrasound can support a clinical impression of torsion.



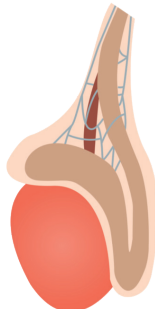
Testicular torsion

The most common symptoms in torsion are swelling and pain. Patients may also have nausea, vomiting, or abdominal pain.

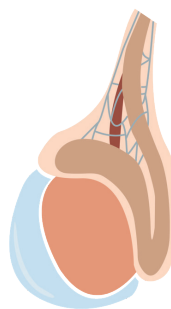
Other findings associated with more common scrotal pathologies may also be noted during a scan:



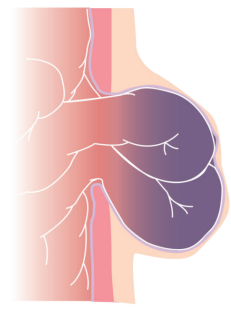
Epididymitis



Orchitis



Hydrocele



Incarcerated hernia